

# Living donor liver transplant from an HIV-positive mother to her HIV-negative child: opening up new therapeutic options

Jean Botha<sup>a</sup>, Francesca Conradie<sup>b,c</sup>, Harriet Etheredge<sup>a,c</sup>,  
June Fabian<sup>a,c</sup>, Mary Duncan<sup>a</sup>, Ahmad Haeri Mazanderani<sup>d,e</sup>,  
Maria Paximadis<sup>d,f</sup>, Heather Maher<sup>a</sup>, Russell Britz<sup>a</sup>,  
Jerome Loveland<sup>a,g</sup>, Bernd Ströbele<sup>a</sup>, Sharan Rambarran<sup>a</sup>,  
Adam Mahomed<sup>a,c</sup>, Alta Terblanche<sup>a</sup>, Marisa Beretta<sup>a</sup>,  
Liam Brannigan<sup>a</sup>, Michael Pienaar<sup>a</sup>, Lindsay Archibald-Durham<sup>a</sup>,  
Allison Lang<sup>a</sup> and Caroline T. Tiemessen<sup>d,f</sup>

See related paper on page 2423

**Objective:** Transplant a liver from an HIV-positive mother to her HIV-negative child to save the child's life.

**Design:** A unique case of living donor liver transplantation from an HIV-positive mother to her HIV-negative child in South Africa. Two aspects of this case are ground-breaking. First, it involves living donation by someone who is HIV-positive and second it involves controlled transplant of an organ from an HIV-positive donor into an HIV-negative recipient, with the potential to prevent infection in the recipient.

**Methods:** Standard surgical procedure for living donor liver transplantation at our centre was followed. HIV-prophylaxis was administered preoperatively. Extensive, ultrasensitive HIV testing, over and above standard diagnostic assays, was undertaken to investigate recipient serostatus and is ongoing.

**Results:** Both mother and child are well, over 1 year posttransplantation. HIV seroconversion in our recipient was detected with serological testing at day 43 posttransplant. However, a decline in HIV antibody titres approaching undetectable levels is now being observed. No plasma, or cell-associated HIV-1 DNA has been detected in the recipient at any time-point since transplant.

<sup>a</sup>Wits Donald Gordon Medical Centre, <sup>b</sup>Clinical HIV Research Unit, <sup>c</sup>Department of Internal Medicine, Faculty of Health Sciences, University of the Witwatersrand, <sup>d</sup>Centre for HIV & STIs, National Institute for Communicable Diseases, Johannesburg, <sup>e</sup>Department of Medical Virology, University of Pretoria, Pretoria, <sup>f</sup>Faculty of Health Sciences, University of the Witwatersrand, and <sup>g</sup>Department of Pediatric Surgery, Faculty of Health Sciences, University of the Witwatersrand, Johannesburg, South Africa. Correspondence to Dr Jean Botha, Transplant Unit, Wits Donald Gordon Medical Centre, 18 Eton Road, Parktown, Johannesburg, 2193, South Africa.

Tel: +27 11 356 6488; e-mail: jeanf.botha@gmail.com

Received: 17 July 2018; accepted: 16 August 2018.

DOI:10.1097/QAD.0000000000002000

ISSN 0269-9370 Copyright © 2018 The Author(s). Published by Wolters Kluwer Health, Inc. This is an open-access article distributed under the terms of the Creative Commons Attribution-Non Commercial-No Derivatives License 4.0 (CCBY-NC-ND), where it is permissible to download and share the work provided it is properly cited. The work cannot be changed in any way or used commercially without permission from the journal.

**Conclusion:** This case potentially opens up a new living liver donor pool which might have clinical relevance in countries where there is a high burden of HIV and a limited number of deceased donor organs or limited access to transplantation. However, our recipient's HIV status is equivocal at present and additional investigation regarding seroconversion events in this unique profile is ongoing.

Copyright © 2018 The Author(s). Published by Wolters Kluwer Health, Inc.

*AIDS* 2018, **32**:F13–F19

**Keywords:** antiretroviral therapy, clinical, functional cure, HIV serodiscordant, liver transplant, liver/hepatitis, living donor, paediatrics, reservoirs, South Africa

## Introduction

The current article reports on a unique liver transplant from an HIV-positive mother to her HIV-negative child. To the best of our knowledge, this is the first such intentional liver transplant of its kind in the world. The transplant saved the life of the child who would certainly have died otherwise. After more than one year of follow-up, the child is thriving and the mother is well. In principle, this transplant has the potential to expand options for HIV-positive organ donors and attenuate the increasing demand for organs. Two aspects of this case are ground-breaking.

First, it involved living liver donation by someone who is HIV-positive. Although HIV-positive to HIV-positive kidney transplants have been performed with acceptable outcomes in South Africa, all the donors have been deceased [1]. Based on the success of this programme, the HIV Organ Policy Equity (HOPE) Act was signed into law in 2013, which legalized the transplant of HIV-positive organs in the USA [2]. Consequently, organs from HIV-positive donors may be transplanted if the centre has obtained approval from their institutional review board and they agree to provide regular safety reports to the Organ Procurement and Transplantation Network. The HOPE Act also stipulates that research in this field must be conducted according to guidelines established by the National Institutes of Health (NIH) and the NIH has initiated the 'HOPE in Action Multicenter Kidney Study' [2,3].

Although in theory the HOPE Act permits donation from an HIV-positive living donor in the USA, we are unaware of any published studies describing the intentional transplantation of organs from HIV-positive living donors. In addition, this is not universally accepted as best clinical practice [4–7]. In our transplant programme, we have always excluded HIV-positive living donors because this procedure might place the donors at increased risk, which we felt was unjustifiable. However, we also realized we needed to acknowledge the enormous progress that has been made in the

management of HIV in South Africa. South Africa has the highest prevalence of HIV (12.6%) and the largest treatment programme in the world – with 3.4 million people on antiretroviral therapy (ART). Prevention of mother-to-child transmission (PMTCT) has reduced new HIV-infection rates in South African children by 84%. This has resulted in a pool of healthy young parents living with well controlled HIV, who have HIV-negative children some of whom, like many children, present for management of life-threatening illnesses.

Second, this case involved controlled transplant of a liver from an HIV-positive donor into an HIV-negative recipient, with the potential to prevent infection in the recipient. By controlled we mean that every effort was made to prevent transmission with prophylaxis, and transmission – if this has taken place – was a known risk of the procedure. To date, all published cases of HIV transmission to seronegative recipients through liver transplantation have been from deceased donors, in uncontrolled circumstances [8,9]. In all these cases, definitive seroconversion has been demonstrated at both an antibody and molecular level through nucleic acid testing.

In 2005, a deceased donor paediatric liver transplant programme was established at Wits Donald Gordon Medical Centre (WDGMC), University of the Witwatersrand, Johannesburg, South Africa. High demand and a critical shortage of deceased donors necessitated expansion of the programme to include living donors in 2013. Subsequently, 60 children have received living donor liver transplants through the programme, which is the only living donor liver transplant programme in sub-Saharan Africa (SSA). Our team is regularly challenged by parents whose children present, critically ill, with liver failure. We are repeatedly asked why being HIV-positive excludes them as living donors. This prompted us to reflect on the emerging needs of those who seek our care. In formulating a considered response, we performed our first living donor liver transplant from an HIV-positive mother to her HIV-negative child.

## Case report

A 7-month-old child with biliary atresia was referred to WDGMC with end stage liver disease. The child underwent a Kasai Portoenterostomy procedure at 12 weeks of age, but biliary drainage was not established. After full evaluation the child was wait-listed for a deceased donor liver transplant with a Pediatric End stage Liver Disease score of 15. The child's mother requested evaluation for living donation but was declined because our policy excluded HIV-positive living donation as per international guidelines [5–7]. Two other close family members were evaluated for living donation but found unsuitable.

Both parents were known HIV-positive. The mother was incidentally diagnosed aged 27 (CD4<sup>+</sup> cell count 169 cells/ $\mu$ l, WHO clinical stage 1) [10]. Four months later she commenced a once daily first-line regimen of ART comprising efavirenz, lamivudine and tenofovir, as per South African national guidelines [9]. She conceived 6 weeks thereafter and remained on this regimen during her pregnancy and postdelivery. The pregnancy was uncomplicated and after delivery, her baby (our patient) received 6 weeks of daily nevirapine prophylaxis for PMTCT, was exclusively formula fed and received standard immunizations as per South Africa's expanded programme [11]. The child was subsequently found to be HIV-negative.

Once children are listed on our programme, the average waiting time for liver transplantation is 49 days. Our patient waited for 181 days and was admitted with life-threatening haematemesis secondary to variceal bleeding despite sclerotherapy. This necessitated ICU admission, intubation, ventilation and further intervention for the bleeding varices. Recovery was complicated by gram negative septicaemia due to a hospital-acquired extended spectrum beta-lactamase *Klebsiella pneumoniae* infection.

Due to our patient's deteriorating health, we became increasingly concerned that without transplantation death was imminent. At the same time, the child's mother repeated her request to be a living donor. It was obvious that this request now merited our most serious consideration if we were to save the life of the child. The case was carefully thought-through from both legal and ethical perspectives, and thorough risk-benefit analysis was undertaken by a multidisciplinary group. The case was ultimately presented for urgent consideration to our institutional review board. Our application was expedited and approved as a pilot study provided the mother fulfilled our criteria for living donation, which she did (IRB approval # M170290). Given her HIV-positive status, the following criteria were also met: CD4<sup>+</sup> cell count more than 200 cells/ $\mu$ l, demonstrable HIV viral suppression for at least 6 months prior to donation; no active tuberculosis (TB) infection; no HIV-associated malignancies or opportunistic infection [12].

Both parents were fully informed of the potential risks to donor and recipient – especially the risk of the recipient contracting HIV. We invited both parents to consent to the procedure, as both are involved in the care of the child and both would be responsible for managing the child's HIV and immunosuppression medications posttransplant. Throughout the process, the parents were assisted by our multilingual independent donor advocate.

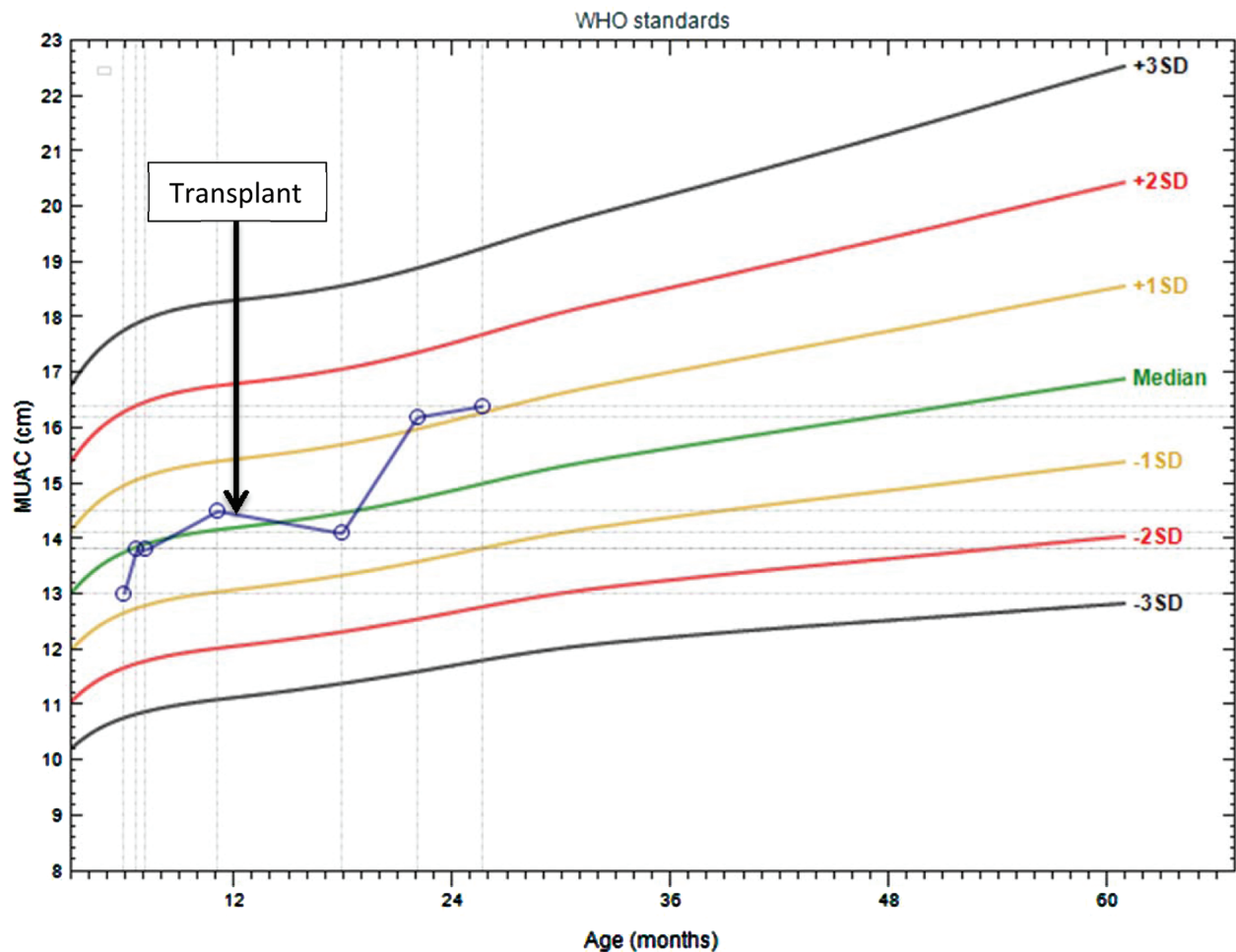
The transplant took place when the child was 13 months old. For the donor, a left lateral segment hepatectomy was performed by the open technique using the Cavitron Ultrasonic Surgical Aspirator for parenchymal transection. The graft was flushed with Custodial preservation solution prior to implantation. The donor's postoperative course was unremarkable and she remains well.

The recipient's operation was standard, with caval preservation and 'piggy-back' implantation. Intraoperatively, 100 mg of methylprednisolone was administered for immunosuppression. Postoperative recovery was delayed by pneumonia and an epigastric collection requiring surgical drainage for which parenteral antibiotics for *Enterococcus faecium* infection were required. Standard prophylaxis was administered for pneumocystis pneumonia and cytomegalovirus infection, but not TB, in line with our policy. Oral corticosteroids and tacrolimus were continued for 6 months, after which corticosteroids were weaned. The recipient remains on oral tacrolimus only, dose adjusted with therapeutic drug monitoring. Our patient has since been well, displaying rapid 'catch up growth' (Fig. 1), has normal-for-age CD4<sup>+</sup> T-cell counts (%), and is followed-up as an outpatient.

## HIV testing and monitoring

As part of standard evaluation of HIV status pretransplant, the recipient tested HIV-1 PCR negative on COBAS AmpliPrep/COBAS TaqManHIV-1 Qualitative Test version 2.0 (CAP/CTM Qual v2.0; Roche Molecular Systems, Inc., Branchburg, New Jersey, USA) and had lost all maternal antibodies as demonstrated by a negative ARCHITECT HIV-1/2 Ag/Ab Combo assay (Abbott Laboratories, Wiesbaden, Germany). To prevent HIV transmission, the recipient was started on ART with raltegravir, lamivudine and abacavir the evening before transplant and has since remained on this regimen. The donor continued her ART regimen throughout her hospital stay.

After transplantation, the recipient's HIV status was monitored using standard laboratory assays. HIV-1/2 serology and HIV-1 virological tests were performed, with evidence of seroconversion and no HIV-1 DNA or RNA detected in peripheral whole blood or plasma (Fig. 2a and b). A western blot performed 225 days



**Fig. 1. Recipient catch-up growth based on middle-upper arm circumference.** Middle-upper arm circumference-for-age according to WHO standards.

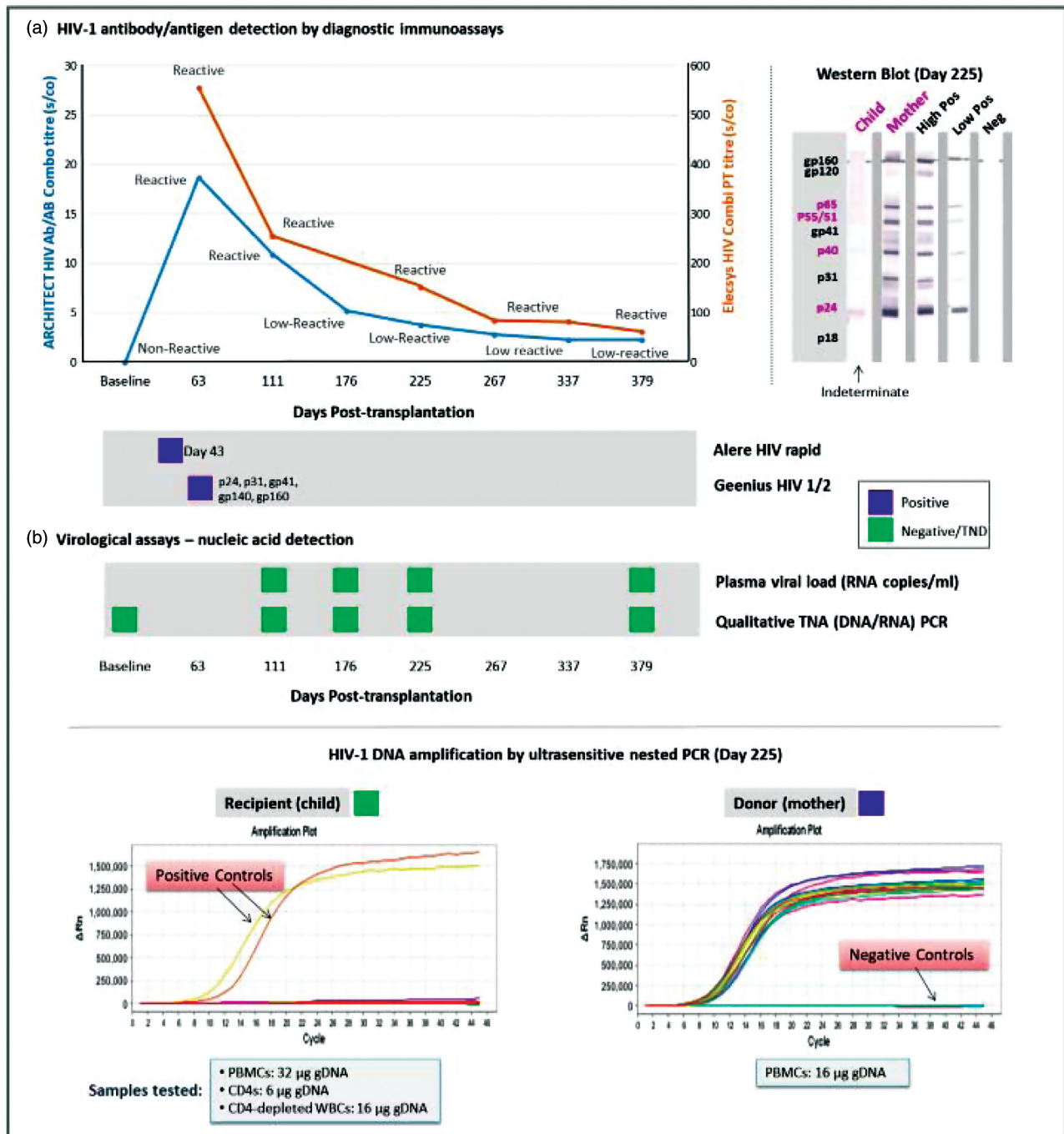
posttransplant yielded an indeterminate picture with antibodies present against HIV-1 Gag (p55/51+/-, p40+/-, p24+) and Pol (p65+/-) antigens but not Env. Ultra-sensitive qualitative nested PCR assay targeting the *integrase* HIV-1 gene was performed to detect HIV-1 total cell-associated DNA (Fig. 2b). No HIV-1 proviral DNA was detected in either the child's peripheral blood mononuclear cells (PBMCs), CD4<sup>+</sup> cells or CD4<sup>+</sup>-depleted leukocytes after assaying 32  $\mu\text{g}$  ( $\approx 4.85 \times 10^6$  cells), 6  $\mu\text{g}$  ( $\approx 9.2 \times 10^5$  cells) and 12.6  $\mu\text{g}$  ( $\approx 1.9 \times 10^6$  cells) of genomic DNA (gDNA), respectively. Using the same assay, proviral DNA was readily detected in all 16 replicates (16  $\mu\text{g}$  gDNA:  $\approx 2.4 \times 10^6$  cells) conducted on gDNA isolated from the mother's PBMCs.

## Discussion

In this case, we have demonstrated that controlled transplantation from an HIV-positive living donor to an

HIV-negative recipient is possible and the short-term surgical outcomes for both donor and recipient are reasonable. Furthermore, it might be possible that under controlled conditions the recipient may not be infected with HIV, however, this will have to be rigorously researched in future work before any conclusions can be drawn. This transplant, although only a single case, has taken the next step in the field of HIV-positive organ donation through the inclusion of an HIV-positive living donor and an HIV-negative recipient and it may open up a new therapeutic option for transplantation. This is timely – as the shortage of donor organs remains a critical obstacle to providing transplant services in South Africa and across the world. This unique type of transplantation could expand access to other SSA countries with high HIV prevalence. There are no other living donor liver transplant programmes in SSA, which means there is no healthcare service for children with end stage liver disease except for that offered in South Africa. However, we are legally able to transplant foreign nationals with appropriate living donors in South Africa [13]. It is important that





**Fig. 2. Time course showing recipient HIV seroconversion, undetectable plasma HIV RNA and cellular DNA reservoir (see next page for figure).** Panel (a) shows results from diagnostic HIV antibody immunoassays conducted at baseline and time points posttransplantation. Specimens with s/co (signal cut-off) at least 1.0 for both ARCHITECT HIV Ag/Ab Combo (Abbott Laboratories, Wiesbaden, Germany) and Elecsys HIV Combi PT (Roche Diagnostics, Mannheim, Germany) assays are interpreted as reactive. Signal cut-off titres 1.0–11.0 are interpreted as low-reactive within the South African National Health Laboratory Service. A rapid Alere assay was positive at day 43, and the Geenius HIV1/2 immunoassay yielded positive reactivity to p24, p31, gp41, gp140 and gp160 at day 63. The GS HIV-1 Western blot (Bio-Rad, Hercules, California, USA) result for the recipient (child) was compared with the donor (mother) profile at 225 days, and with controls that are high positive, low positive, and HIV-negative. Low-reactive bands (p65, p55/51, p40, p24) in the child are indicated in colour – diagnosis indeterminate. Panel (b) shows results from all nucleic acid (RNA/DNA) assays conducted at indicated times posttransplantation. Viral load results (assay sensitivity of detection: <20 RNA copies/ml) were all reported as target not detected – tested by CAP/CTMv2.0 (days 111 and 225) and Abbott RealTime assay (day 176). Qualitative total nucleic acid assays were negative – CAP/CTMv2.0 (baseline, days 111 and 225) and Abbott RealTime assay (day 176). Using an in-house qualitative ultrasensitive nested RNA IN-qPCR all recipient samples were negative and all donor samples were positive (cell subsets and total amounts of DNA tested for each are indicated).

such a procedure is backed-up by careful donor advocacy and patient education, and that the decision to undertake such a transplant is supported by a strong ethics framework – as it was in our case.

A critical question for us at present is whether or not, under controlled circumstances, HIV transmission to the recipient might be preventable. At the time of writing, the HIV status of our recipient is equivocal and we acknowledge that HIV infection in these circumstances can be extremely difficult to document, particularly in children on ART. There is no doubt that the recipient was seronegative prior to transplantation. We have evidence of seroconversion within 43 days of the transplant with a demonstrable decline in HIV antibody titres approaching undetectable levels by 379 days. However, at no time point could any plasma HIV-1 RNA or cell-associated HIV-1 DNA be detected. Lack of detection of HIV-1 proviral DNA in our recipient was further confirmed by ultrasensitive nested PCR.

A number of scenarios might explain these results: first, a very small but measurable reservoir exists in the periphery if HIV-1 spread has occurred despite preexposure ART and continued ART – but is below detection limits of all currently available laboratory assays, second, the detectable reservoir is limited to the infected donor liver and no new infection of recipient cells has taken place – with no detectable HIV-1 DNA in the peripheral circulation, third, the seroconversion event, ordinarily associated with HIV-1 positive status, is not the child's response but rather is generated by maternal liver immune cells, resident or transferred with the graft, fourth, the HIV antibodies are produced by the child's B cells following presentation of HIV antigens by liver antigen presenting cells. Irrespective, this is an HIV-antibody response that wanes, suggesting there is insufficient ongoing antigenic stimulation to maintain detectable responses.

Historically, in acute infection with HIV-1, high levels of antigen precede the development of HIV-specific antibodies and at least some low level of ongoing viral replication is needed to maintain detectable responses even with suppressive ART in chronic infection. It is increasingly reported that when ART is initiated in early stages of infection, a large proportion of HIV-1 infected children and adults subsequently develop nonreactive HIV-antibody results [14–16]. For all these HIV-antibody negative cases, there were definitive molecular tests that indicated the presence of HIV-1 infection at the outset. Molecular tests in this recipient have demonstrated no evidence of infection, which makes this case unique.

Although we were not able to test any sample of donor liver prior to transplantation, the liver is known to contain many resident cell types that can be productively infected *in vitro* and HIV-1 RNA has also been detected

*in vivo* [17]. However, a study of 42 simian immunodeficiency virus (SIV)-infected macaques, revealed productive SIV infection in the liver of only one animal, whereas in contrast other tissues (jejunum, colon, lymph nodes) of all animals had high numbers of infected cells [18]. These findings suggest the liver may not be a major reservoir for replicating virus *in vivo*, although may harbour latently infected cells.

For our recipient, risk of infection needs to be considered in the context of factors unique to the transplant setting including the inflammatory environment associated with alloresponses despite immunosuppressive treatment [19]. This may be associated with increased target cells for HIV-1 infection, preexposure ART and ongoing ART which prevents infection of new cells and the processes and immune responses involved in liver regeneration [20] which could conceivably clear virus or reduce the number of infected cells present.

There may come a time in the future when we are obliged to consider a provocative discontinuation of ART to definitively establish HIV serostatus, as this may be the only way of determining whether HIV has been transmitted to the recipient. One would need to consider whether this is ethical and feasible, and if so, at what time point this should be considered. However we hope to undertake further transplants of this nature as part of an approved research study (IRB approval # M171035) before making any such decision. Future cases will involve much more detailed HIV testing and sampling from the outset, including collecting samples intraoperatively. It is hoped that more extensive testing will evolve our understanding of this novel type of transmission and may ultimately provide definitive guidance regarding management. At present, the team have agreed to keep our recipient on ART for a minimum of 2 years. Whether we eventually discontinue ART will be carefully considered and based on further insights from our future research, balancing risk and benefit.

## Acknowledgements

Author contributions: J.B.: PI, main surgeon, conceptualised study, drafts of article, approval of final article; F.C.: Co-PI, HIV management of patient, input on drafts and final article; H.E.: ethics and regulatory, article drafting and input on all versions; J.F.: research conceptualisation, article drafting and input on all versions; M.D.: Transplant coordinator involved in clinical management of patient, input on final draft; A.H.M.: HIV serostatus investigations, article drafting and input on final version; M.P.: HIV serostatus investigations, article drafting and input on final version; H.M.: study data management and input on final version of article; R.B.: clinical management of patients and input on final version of article; J.L.: clinical management of

patients and input on final version of article; B.S.: clinical management of patients and input on final version of article; S.R.: clinical management of patients and input on final version of article; A.M.: clinical management of patients and input on final version of article; A.T.: clinical management of patients and input on final version of article; M.B.: clinical management of patients and input on final version of article; L.B.: clinical management of patients and input on final version of article; M.P.: clinical management of patients and input on final version of article; LA-D: clinical management of patients and input on final version of article; A.L.: Clinical management of patients and input on final version of article; C.T.T.: HIV serostatus investigations, article drafting and input on all versions of article.

**Funding:** A portion of this work is based on the research supported by grant awards from the South African Research Chairs Initiative of the Department of Science and Technology and National Research Foundation of South Africa.

### Conflicts of interest

There are no conflicts of interest.

### References

- Muller E, Barday Z, Mendelson M, Kahn D. **HIV-positive-to-HIV-positive kidney transplantation – results at 3 to 5 years.** *N Engl J Med* 2015; **372**:613–620.
- Durand CM, Segev D, Sugarman J. **Realizing HOPE: the ethics of organ transplantation from HIV-positive donors.** *Ann Intern Med* 2016; **165**:138–142.
- NIH clinical trial to track outcomes of kidney transplantation from HIV-positive donors to HIV-positive recipients. 2018. <https://www.nih.gov/news-events/news-releases/nih-clinical-trial-track-outcomes-kidney-transplantation-hiv-positive-donors-hiv-positive-recipients>. [Accessed 31 July 2018].
- Clinical guidelines for adult live donor liver transplantation. Vancouver: British Columbia Transplant; 2016. <https://docplayer.net/50233518-Clinical-guidelines-for-adult-live-donor-liver-transplantation.html>. [Accessed 17 July 18].
- Policies. United States of America: organ procurement and transplantation network; 2018. [https://optn.transplant.hrsa.gov/media/1200/optn\\_policies.pdf](https://optn.transplant.hrsa.gov/media/1200/optn_policies.pdf). [Accessed 17 July 2018].
- Living donor liver transplantation. British Transplantation Society; 2015. [https://bts.org.uk/wp-content/uploads/2016/09/03\\_BTS\\_LivingDonorLiver-1.pdf](https://bts.org.uk/wp-content/uploads/2016/09/03_BTS_LivingDonorLiver-1.pdf). [Accessed 17 July 2018].
- Clinical guidelines for organ transplantation from deceased donors. The Transplantation Society of Australia and New Zealand; 2016. [http://www.donatelife.gov.au/sites/default/files/TSANZ%20Clinical%20Guidelines%20for%20Organ%20Transplantation%20from%20Deceased%20Donors\\_Version%201.0\\_April%202016.pdf](http://www.donatelife.gov.au/sites/default/files/TSANZ%20Clinical%20Guidelines%20for%20Organ%20Transplantation%20from%20Deceased%20Donors_Version%201.0_April%202016.pdf). [Accessed 17 July 2018].
- Lin SN, Tsai MK, Luo CY, Lee CY, Hu RH, Lee JM, Lai HS. Outcomes of Solid Organ Transplantation from an HIV Positive Donor to Negative Recipients. 2016 American Transplant Congress; 2016. <https://atcmeetingabstracts.com/abstract/outcomes-of-solidorgan-transplantation-from-an-hiv-positive-donor-to-negative-recipients/>. [Accessed 17 July 2018].
- Wispelwey BP, Zivotofsky AZ, Jotkowitz AB. **The transplantation of solid organs from HIV-positive donors to HIV-negative recipients: ethical implications.** *J Med Ethics* 2015; **41**:367–370.
- World Health Organization. *WHO case definitions of HIV for surveillance and revised clinical staging and immunological classification of HIV-related disease in adults and children.* Geneva: WHO; 2007. Available at: <http://www.who.int/hiv/pub/guidelines/hivstaging/en/> [Accessed 17 July 2018].
- National Department of Health. *National consolidated guidelines for the prevention of mother-to-child transmission of HIV (PMTCT) and the management of HIV in children, adolescents and adults.* Pretoria: South Africa: National Department of Health; 2015. Available at: [https://www.unicef.org/southafrica/resources\\_19247.html](https://www.unicef.org/southafrica/resources_19247.html) [Accessed 17 July 2018].
- Bhagani S, Sweny P, Brook G. **Guidelines for kidney transplantation in patients with HIV disease.** *HIV Med* 2006; **7**:133–139.
- National Health Act No. 61 of 2003. Government of the Republic of South Africa, Government Gazette, 2004, 469(869). South Africa 2004. <https://www.gov.za/sites/default/files/a61-03.pdf> [Accessed 17 July 2018].
- Kuhn L, Schramm DB, Shiao S, Strehlau R, Pinillos F, Technau K, et al. **Young age at start of antiretroviral therapy and negative HIV antibody results in HIV-infected children when suppressed.** *AIDS* 2015; **29**:1053–1060.
- Payne H, Mkhize N, Otjombe K, Lewis J, Panchia R, Callard R, et al. **Reactivity of routine HIV antibody tests in children who initiated antiretroviral therapy in early infancy as part of the Children with HIV Early Antiretroviral Therapy (CHER) trial: a retrospective analysis.** *Lancet Infect Dis* 2015; **15**:803–809.
- de Souza MS, Pinyakorn S, Akapirat S, Pattanachaiwit S, Fletcher JL, Chomchey N, et al. **Initiation of antiretroviral therapy during acute HIV-1 infection leads to a high rate of nonreactive HIV serology.** *Clin Infect Dis* 2016; **63**:555–561.
- Crane M, Iser D, Lewin SR. **Human immunodeficiency virus infection and the liver.** *Hepatology* 2012; **4**:91–98.
- Ahsan MH, Gill AF, Alvarez X, Lackner AA, Veazey RS. **Kinetics of liver macrophages (Kupffer cells) in SIV-infected macaques.** *Virology* 2013; **446**:77–85.
- Germani G, Rodriguez-Castro K, Russo FP, Senzolo M, Zanetto A, Ferrarese A, Burra P. **Markers of acute rejection and graft acceptance in liver transplantation.** *World J Gastroenterol* 2015; **21**:1061–1068.
- Li N, Hua J. **Immune cells in liver regeneration.** *Oncotarget* 2017; **8**:3628–3639.